Rohilkhand Journal of AYUSH Research

Clinical Case Study

Clinical Management of *Bhagandara* (Fistula-in-ano) with *Snuhi Apamarga Kshar Sutra* Ligation: A Case Study

Dr. Mansi *1, Dr. Abhay Prakash 2, Dr. Arun Sharma 3

1*Assistant Professor, Department of Shalya Tantra, Rohilkhand Ayurvedic Medical College and Hospital, Bareilly

2 HOD & Associate Professor, Department of Shalya Tantra, Rohilkhand Ayurvedic Medical College and Hospital, Bareilly

3 Associate Professor, Department of Rasa Shastra and Bhaishajya kalpana, Rohilkhand Ayurvedic Medical College and Hospital, Bareilly

https://doi.org/10.65001/RJAR.2026.V2I1N6

ABSTRACT:

Background: *Bhagandara* (fistula-in-ano) is a chronic anorectal condition that may cause persistent pain, discharge, and difficulty maintaining perianal hygiene. Its management can be challenging, particularly when the external opening is not clearly visible. *Kshar* Sutra ligation is a minimally invasive para-surgical approach used in the management of this condition.

Method: This case study describes the management of a 35-year-old male who presented with pain and intermittent purulent discharge from the anal region for one year. Clinical examination and MRI fistulogram identified a fistulous tract with an internal opening at the 6 o'clock position, extending towards the 9 o'clock position, without a visible external opening. *Snuhi Apamarga Kshar Sutra* ligation was performed under local anaesthesia after creating an artificial external opening. The *Kshar Sutra* was replaced weekly using the railroad technique, and the patient was assessed for pain, discharge, wound healing, and complications.

Result: Progressive cutting and healing of the fistulous tract were observed during weekly follow-up. Discharge and induration gradually decreased, with healthy granulation tissue formation. Complete tract healing was achieved by the fourth week. No significant complications or recurrence were reported during the documented follow-up period.

Conclusion: *Kshar Sutra* therapy is considered an effective and economical treatment modality for *Bhagandara* (fistula-in-ano). The medicated thread is described as possessing *Chedana, Bhedana, Lekhana,* and *Tridoshaghna* properties, which may help in tract cutting, removal of unhealthy tissue, and simultaneous promotion of healthy granulation. In this single-patient case, *Snuhi Apamarga Kshar Sutra* ligation resulted in satisfactory healing with minimal complications and complete closure of the fistulous tract. The procedure may serve as a minimally invasive treatment option for selected cases of *Bahgandara* (fistula-in-ano).

Keywords: *Bhagandara, Kshar Sutra*, Fistula-in-ano, *Snuhi Apamarga Kshar sutra*

Rohilkhand Journal of AYUSH Research

INTRODUCTION:

Bhagandara is described under *Ashtamahagada* by *Acharya Sushruta* due to its complicated nature and tendency for recurrence.[1] The term *Bhagandara* is derived from two words: *"Bhaga"* and *"Darana."* The condition which causes tearing or destruction in the region of *bhaga, guda,* and *basti* is termed *Bhagandara*.[2]

Bhagandara is considered one of the most challenging anorectal disorders described in *Ayurveda* because of its chronic course, frequent recurrence and involvement of the delicate tissues around the anal canal. Patients commonly experience persistent pain, recurrent discharge, swelling, and discomfort during sitting and defecation, which can significantly affect their daily activities and overall quality of life.

Fistula-in-ano is described as *Bhagandara* in *Ayurvedic* classics, particularly in *Sushruta Samhita*. [3,4]

In modern medicine, A fistula-in-ano is an abnormal tract that connects the anal canal to the skin surrounding the anus. It is generally lined with granulation tissue and has an internal opening within the anal canal and an external opening on the perianal skin. In some cases, multiple secondary tracts may arise from a single internal opening and extend into the surrounding tissues.[5] It is a persistent inflammatory condition characterized by recurrent discharge of pus from the perianal region. Patients may experience repeated episodes of infection and recurrence even after treatment. The commonly accepted explanation for its development is that infection originates in the anal glands, spreads to the surrounding tissues, and may lead to the formation of a perianal or perirectal abscess, which can subsequently develop into a fistulous tract. [6,7]

An anal abscess is usually the initial acute manifestation of infection, while fistula-in-ano develops as a persistent tract that may remain after the abscess has drained or healed incompletely. Patients may experience symptoms of varying severity, including pain, recurrent discharge, irritation, and difficulty maintaining perianal hygiene. In more severe cases, the infection may progress and lead to systemic complications such as sepsis.[8] Despite advances in surgical techniques, the management of fistula-in-ano continues to be a clinical challenge because treatment must achieve healing while preserving anal sphincter function and preventing recurrence.[9]

Kshar Sutra therapy has emerged as a widely accepted modality in the management of fistula-in-ano due to its low recurrence rates and its unique ability to simultaneously excise, debride, and promote healing of the fistulous tract. The procedure is typically performed under local anesthesia, and the medicated thread is periodically replaced using the railroad technique until complete transection and healing of the tract are achieved.

Modern surgical procedures are effective but may be associated with recurrence, delayed healing, or sphincter injury in selected cases. *Kshar Sutra* therapy offers a minimally invasive alternative that promotes simultaneous cutting, drainage, debridement, and healing while preserving sphincter function.

This para-surgical approach facilitates effective

healing while preserving the anatomical and functional integrity of the anal sphincters, thereby minimizing the risk of incontinence. Substantial clinical evidence supports its efficacy, demonstrating a consistently low recurrence rate. *Kshar Sutra* therapy is now recognized as a scientifically validated treatment for *Bhagandara* (fistula-in-ano). Among its various forms, *Apamarga Ksharasutra* has shown particularly high therapeutic efficacy and has been standardized by the Central Council for Research in *Ayurvedic* Sciences (CCRAS), the apex governmental body for research in traditional Indian medicine.[10]

CASE REPORT

A 35-year-old male presented to the *Shalya Tantra* OPD of Rohilkhand Ayurvedic Medical College and Hospital with complaints of pain and intermittent purulent discharge from the anal region for one year. The patient had received prior conservative management without significant improvement, and symptoms persisted with recurrent discomfort and discharge. There was no history of systemic illness, allergy, or significant family history.

On general examination, the patient was moderately built, with stable vital parameters (pulse: 72/min; blood pressure: 120/84 mmHg). Systemic examination of the cardiovascular, respiratory, gastrointestinal, and urogenital systems was within normal limits.

Local examination in the lithotomy position revealed no visible external opening in the perianal region, although mild tenderness was noted. Palpation demonstrated a laterally extending indurated tract. On probing through the anal canal, an internal opening was identified at the 6 o'clock position, with the tract extending towards the 9 o'clock position. MRI fistulogram confirmed a fistulous tract extending from the internal opening at 6 o'clock to the 9 o'clock position.



Fig. 1 MRI Report



Fig. 2 Diagrammatic presentation of FIA

Based on clinical and radiological findings, the case was diagnosed as fistula-in-ano (Bhagandara).

TREATMENT PROCEDURE

Pre-operative Preparation

The patient was advised to undergo routine pre-operative investigations including complete blood count, bleeding time, clotting time, erythrocyte sedimentation rate, random blood sugar, viral markers (HIV, HBsAg, HCV), urine routine and microscopy, liver and kidney function tests, chest X-ray (PA view), and electrocardiogram. All parameters were within normal limits. Written informed consent was obtained prior to the procedure. Standard pre-operative preparation was carried out, including local part preparation. Prophylactic tetanus toxoid (0.5 ml) was administered, and a sensitivity test dose of 2% plain xylocaine was given before proceeding with the intervention.

Operative Procedure

The patient was positioned in lithotomy under strict aseptic precautions, followed by painting and draping of the operative field. Local anesthesia was achieved using 2% xylocaine infiltration around the perianal region, along with gentle anal dilatation. Probing confirmed the internal opening at the 6 o'clock position with a tract extending towards the 9 o'clock position. In the absence of a natural external opening, an artificial external opening was created at the 9 o'clock position to facilitate drainage. A probe was then carefully negotiated through the tract from the external to the internal opening. Subsequently, *Snuhi Apamarga Kshar Sutra* was threaded through the tract and tied securely to ensure adequate placement along the entire fistulous pathway, allowing simultaneous cutting and healing. Haemostasis was achieved, and sterile dressing was applied using *Jatyadi Taila*. The procedure was completed without any intraoperative complications.

Regular weekly replacement of the *Kshar Sutra* was performed using the railroad technique under aseptic precautions. During each visit, the wound was assessed for discharge, induration, granulation tissue formation, pain, and signs of infection.

Post-operative Management

Postoperatively, the patient was prescribed *Saptavinshati Guggulu* 250 mg (two tablets twice daily after meals), *Abhyarishta* 20 ml mixed with an equal quantity of water twice daily after meals, and *Triphala Churna* 5 g at bedtime to promote wound healing and maintain regular bowel movements. The patient was also advised to administer *Jatyadi Taila Matra Basti* (3 ml per rectum daily), as it helps promote wound healing, relieves postoperative pain, and provides lubrication and protection to the anal canal, thereby facilitating comfortable defecation. In addition, warm sitz baths with lukewarm water were recommended to maintain local hygiene, reduce pain, and minimize postoperative discomfort. The patient was further advised to avoid prolonged sitting, consume a high-fiber diet, ensure adequate fluid intake, and maintain proper perianal hygiene to prevent constipation and support optimal healing of the fistulous tract.

Rohilkhand Journal of AYUSH Research

CLINICAL IMAGES

Fig 3: Probing done from external opening to internal opening



Fig 4: Kshar sutra threading done in the fistulous tract



Fig 5: Kshar sutra ligation done with complete haemostasis achieved



FOLLOW-UP AND RESULTS

Week	RESULT
1st Week	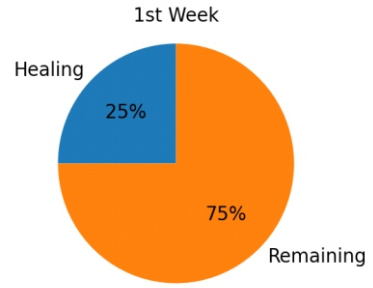
2nd Week	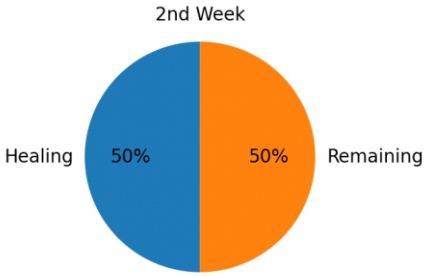
3rd Week	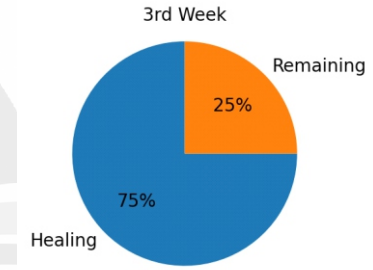
4th Week	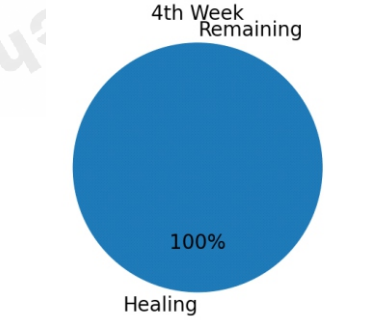

The patient was followed up at weekly intervals, during which the Kshar Sutra was replaced every seven days using the standard railroad technique. With each successive sitting, gradual cutting of the fistulous tract was

observed along with simultaneous healing, evidenced by progressive reduction in discharge and induration. Sequential follow-ups demonstrated healthy granulation tissue formation and steady contraction of the tract without any signs of secondary infection or complications. By the end of the treatment period, complete cut-through and healing of the tract were achieved. The patient remained asymptomatic throughout subsequent follow-ups, with no evidence of recurrence, thereby indicating a favorable clinical outcome.

FOLLOW-UP IMAGES

Fig 6: 1st week



Fig 7: 2nd week



Fig 8: 3rd week



Fig 9: 4th week



DISCUSSION

This case clearly demonstrates the practical utility and effectiveness of Snuhi Apamarga Kshar Sutra in managing Bhagandara (fistula-in-ano), especially in an unusual presentation where no external opening was initially visible. The favorable outcome in this patient was largely the result of careful clinical evaluation, supported by imaging, and the thoughtful selection of Kshar Sutra therapy. The approach not only followed classical Ayurvedic principles but also incorporated sound clinical judgment, allowing successful management of a challenging fistulous tract with complete healing and no recurrence during follow-up.

The successful management observed in this case supports the classical Ayurvedic concept that Kshar Sutra acts through Chedana, Bhedana, Lekhana, and Ropana properties. The medicated coating of Snuhi latex, Apamarga Kshara and Haridra powder provides antimicrobial, anti-inflammatory, debridement, and wound-healing actions, facilitating progressive transection of the tract with healthy granulation tissue formation.

Sequential follow-up demonstrated gradual reduction in pain, discharge, and induration with satisfactory healing at every weekly sitting. No secondary infection, bleeding, fecal incontinence, or recurrence was observed

during the follow-up period, indicating both safety and effectiveness of the therapy in this patient.

This case also emphasizes the importance of MRI fistulogram in identifying the internal opening and course of the tract before intervention, thereby improving treatment planning and successful execution of Kshar Sutra ligation.

CONCLUSION

Kshar sutra therapy is an effective and economical treatment modality for *Bhagandara* (fistula-in-ano). The medicated thread possesses *Chedana, Bhedana, Lekhana* and *Tridoshaghna* properties, which help in cutting the tract, removing unhealthy tissue, and promoting healthy granulation simultaneously.

In this case, *Snuhi Apamarga Kshar sutra* provided satisfactory results with minimal complications and complete healing of the tract. Hence, *Kshar sutra* therapy remains a safe, effective, and minimally invasive procedure for the management of fistula-in-ano.

REFERENCES

1. Acharya Sushruta. Sushruta Samhita, with Dalhana's Nibandhasangraha commentary. Edited by Jadavji Trikamji Acharya and Narayan Ram Acharya. Varanasi: Chowkhambha Surabharati Prakashana; 2008. Sutrasthana, Chapter 33, Verse 4, p. 144.
2. Acharya Sushruta. Sushruta Samhita. Ayurveda Tattvasandipika Hindi commentary by Ambikadatta Shastri. Varanasi: Chaukhamba Sanskrit Sansthan; 2011. Nidanasthana, Chapter 4, Verse 4, p. 317.
3. Sushruta. Sushruta Samhita. Ayurveda Tattvasandipika Hindi commentary by Ambikadatta Shastri. Varanasi: Chaukhamba Sanskrit Sansthan; [edition and year to be verified]. Nidanasthana, Chapter 4, Verse 12, p. 246.
4. Tripathi B. Ashtanga Hridayam: Nirmala Hindi commentary. Delhi: Chaukhambha Sanskrit Sansthan; [publication year to be verified]. Uttarsthana, Chapter 28, Verse 5, p. 109.
5. Saxena P, Yadav SS. A prospective study of fistula in ano with reference to clinicopathology, imaging and management. Int Surg J.2019;6:1664-72.
6. Poggio JL.Fistula-in-anotreatment and management. Available at: https://emedicine.medscape.com/article/190234-treatment. Accessedon15 February 2017.
7. Steele SR, Kumar R, Feingold DL. Practice parameters for treatment of fistula-in-ano--supporting documentation. The standards practice task force. Dis Colon Rectum. 1996;39(12):1363-72
8. Phillips J, Lees N, Arnall F. Current management of fistula-in-ano. Br J Hosp Med.2015;76(3):142-4.
9. Williams JG, Farrands PA, Williams AB. The treatment of anal fistula: ACPGBI position statement. Colorectal Dis. 2007;9(4):18-50.
10. Dwivedi AK, Chaudhary M, Kulshreshtha DK, Sarin JP. Standardization of Ksharasutra. Journal of Research in Ayurveda and Siddha. 1991; 12:85-92. [Google Scholar]

Cite this article as (NLM):

Mansi, Prakash A, Sharma A. Clinical management of Bhagandara (fistula-in-ano) with Snuhi Apamarga Kshar Sutra ligation: A case study. Rohilkhand Research. 2026 Mar-Aug;2(1):60-66.
doi:10.65001/RJAR.2026.V2I1N6

Corresponding author: ***drmansiverma5@gmail.com***

Submitted: 09/054/2026 | *Revised:12/06/2026* | *Accepted:03/07/2026* | *Published:30/09/2026*